



CRYPTOCOCCAL MENINGOENCEPHALITIS: A QUICK GUIDE FOR CLINICIANS

Atul K Patel MD, FIDSA, Ketan K Patel MD
Vedanta Institute of Medical Sciences
Ahmedabad

Introduction

Cryptococcal meningoencephalitis (CM) is a universally fatal fungal infection if not treated. CM is caused by encapsulated yeast, *Cryptococcus neoformans* that is found ubiquitously in soil, dust, and pigeon droppings. Four serotypes (A to D) exist, of which three cause human infections; *C. neoformans* (most common), *v. gattii*, and *v. grubii*. Infection is acquired by inhalation of the yeast, giving rise to local pulmonary infection. The person usually remains asymptomatic and functioning innate immune cells clear this local infection. But in a susceptible host, brief cryptococemia with dissemination of infection to the central nervous system (CNS), lymph nodes, skin and prostatic tissues follows pulmonary infection. Susceptible hosts comprise of HIV infected patients (CD4 cell count <100/cmm), monoclonal antibody containing treatment especially TNF alfa inhibitor (Infliximab, Adalimumab) and steroids. *C. gattii* can produce infection in immunocompetent hosts as well; it is more virulent with greater fluconazole resistance as compared to *C. neoformans*. Though the commonly used term is cryptococcal meningitis, in majority of patients, it is cryptococcal meningoencephalitis (CM) with a prevalence rate of 6-30% in HIV infected patients, more commonly seen in sub-Saharan Africa. Current estimates indicate that every year, nearly 1 million cases of cryptococcal meningitis are diagnosed worldwide and the disease accounts for more than 600,000 deaths. Despite antifungal therapy, CM carries high mortality of 30-50% and high morbidity in survivors. Irreversible blindness and deafness and neurocognitive abnormalities are common complications.

Clinical Presentation

CM commonly presents as a subacute meningitis or meningoencephalitis with fever, malaise, and headache in HIV infected patients. Seizures, altered mental status, focal neurological deficits are found in patients with late diagnosis or patients with high fungal load and are associated with poor outcome. It's not uncommon to have only headache as the sole presenting symptom for CM in HIV patients. Classical features of meningitis like photophobia, neck stiffness are generally absent in HIV infected patients and seen in one third to one quarter of patients only.

Diagnosis

Diagnosis CM is commonly arrived by CSF examination with India ink preparation (Figure 1), cryptococcal antigen (CrAg) and culture. Patients presented with altered sensorium or with focal neurological deficit should undergo neuroimaging studies prior to a lumbar puncture. Abnormal mental status on presentation, high CSF opening pressure, CSF WBC count <20 and high CrAg titer > 1:1024 are markers of a poor prognosis.

Treatment

CM treatment has two components; antifungal therapy and management of raised intracranial pressure (ICP).

Message from the Editor

It is a pleasure to present to you the first newsletter of this year. We have a medley of information relating to fungal diseases. First and foremost is a quick review on cryptococcal meningitis. While one always has a high index of suspicion for this infection in those who are HIV infected, one should not forget to look for it in immunocompetent hosts and those immunocompromised due to other causes. Then we discuss a urinary tract infection due to a rare fungus *Eupenicillium meridianum* which highlights the need for good infection control measures while conducting urologic or endoscopic procedures as well as the need for molecular identification in a reference laboratory when the isolate is an unusual fungus. Finally we have a case of invasive pulmonary aspergillosis in a patient with HIV where treatment was complicated by various drug interactions between voriconazole and anti retroviral drugs.

The Clinical Infectious Diseases Society (CIDS) looks forward to continued collaboration with FISF. CIDS members are closely involved in the diagnosis and management of fungal infections and CIDS welcomes you to attend its annual conference **CIDSCON from Aug 23-25 at Kochi (www.cidsindia.org)**, where many sessions will deal with fungal infections

Welcoming your feedback

Editor

Dr. Tanu Singhal; Consultant Pediatrics and Infectious Disease,
Kokilaben Dhirubhai Ambani Hospital, Mumbai

Feedback is welcome at

tanusinghal@yahoo.com, tanu.singhal@relianceada.com

Regional Mycocon 2019 : 9th and 10th March, Hyderabad

Fungal Infection e-Course

2 Day Fungal Infection Training Courses

See website www.fisftrust.org for details

Antifungal therapy

Goal of antifungal therapy for patients with CM is to achieve a rapid yeast clearance from CSF. Slower rates of CSF yeast clearance have been shown to be associated with increased mortality at both 2 and 10 weeks. Combination therapy containing Amphotericin B (deoxycholate or liposomal) with flucytosine (5FC) is associated with rapid CSF sterilization and is clearly the regimen of choice for the treatment of CM. When 5 FC is not available or can't be used due to cost or toxicity, fluconazole at the dose of 800mg/day

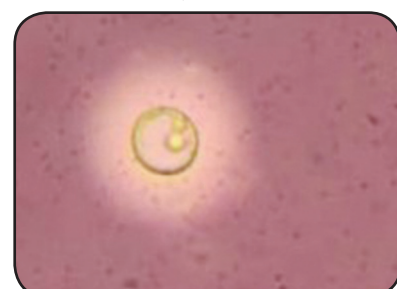

Figure 1: India Ink preparation showing capsulated yeast

is an inferior but acceptable alternative, in combination with amphotericin B. Recommended dosage for amphotericin B deoxycholate (ABDC) is 0.7 – 1 mg/kg/day with 5FC 100mg/kg/day or liposomal amphotericin B (L-AmB) 3–4mg/kg/day with 5FC 100mg/kg/day for two weeks. Combination therapy of amphotericin B with 5 FC is associated with 40% lower hazard of mortality and increase fungal clearance rate compared to amphotericin monotherapy.

Treatment of CM in resource-limited settings is challenging mainly due to

- Cost involved in 2 weeks induction therapy for amphotericin B and 5FC
- Accessibility of 5 FC
- Hospitalization and close laboratory monitoring required for IV amphotericin B and 5FC for its associated toxicities.

A recent study from Molloy SF et al comparing all oral regimen (Fluconazole + 5FC) with 1 week and 2 weeks of ABDC with 5 FC or fluconazole (Total 5 arms), found 1 week of ABDC + 5FC is associated with better survival of patients with CM in a resource limited settings. For patients who are intolerant to amphotericin B and cannot afford liposomal amphotericin B, oral regimen containing fluconazole (400–800 mg daily) combined with 5FC is also a potential alternative to amphotericin B regimens in the same study. Fluconazole alone is inferior to amphotericin B for induction therapy and is recommended only for patients who cannot tolerate or do not respond to standard treatment. If it is used for primary induction therapy, the starting daily dose should be 1200 mg.

Induction therapy should be followed by consolidation therapy with fluconazole 400–800 mg per day for 8 weeks followed by maintenance therapy of fluconazole 200mg/day. WHO recommends maintenance therapy for 1 year, to be discontinued if CD4 > 200/cmm.

A recent publication looking at single dose of L-AmB, showed promising results in phase two study. In this study, three short courses of L-AmB were compared, L-AmB 10mg/kg day 1 (single dose), L-AmB 10mg/kg Day 1 and 5mg/kg day 3 (two dosage), L-AmB 10mg/kg day 1, and 5 mg/kg on day 3 & 7 (three dosage) along with fluconazole 1200mg/ day for two weeks, were found to be equal compared to standard dosage using L-AmB 3–4 mg/kg for two weeks along with 1200 mg fluconazole.

Treatment principles and regimen of CM in organ transplant and the immunocompetent host is similar to that HIV infected patients, except duration of induction therapy with L-AmB with 5 FC is prolonged and should be continued for 6 weeks as compared to HIV patients. Consolidation and maintenance phase is similar to that in HIV host with fluconazole.

Management of raised intracranial pressure (ICP)

Raised ICP in CM is caused by mechanical blockade by presence of live or dead cryptococci at arachnoid villi, leading to failure of CSF reabsorption. ICP correlates with CSF fungal burden. A considerable number (40%) of deaths in CM occurs during 3–10 weeks of treatment mainly due to raised ICP despite early diagnosis and prompt antifungal therapy. Therapeutic lumbar puncture (LP) with removal of large volume of CSF effectively lowers ICP in a patient with high opening CSF pressure. The safe maximum volume of CSF that can be drained at one lumbar puncture is unclear, but up to 30 ml of CSF can be removed in patients with high pressure, with checking of pressure after each 10 ml removed. Suggested frequency of LP in CM patients is at 48–72 hours, 7 and 14 days (strongly consider, unless patient is asymptomatic). Therapeutic LP is associated with mortality benefit, regardless of intracranial pressure. Those with normal opening pressures at baseline who did not receive a repeat therapeutic LP had higher 10-day mortality than those who received an additional therapeutic LP. The average effect of therapeutic LPs was to reduce the risk of mortality by 69% (95% CI, 18%–88%). Other methods of decreasing

ICP such as acetazolamide, mannitol or steroids should not be routinely used. It is important to note that adjunctive use of dexamethasone in patients with HIV associated cryptococcal meningitis did not reduce mortality but was associated with increased disability, adverse effects and delayed microbiologic clearance.

Antiretroviral Therapy in CM

Initiation of antiretroviral therapy in HIV infected individual is tricky as clinicians should be watchful for life threatening immune reconstitution inflammatory syndrome (IRIS). Optimal timing for initiation of ART in patients with acute cryptococcal meningitis is not well defined. Results of Cryptococcal Optimal ART Timing (COAT) trial suggest better survival in delayed ART arm as compared to simultaneous treatment arm while receiving anti-Cryptococcus drugs. Additionally, early ART is not associated with improved CSF cryptococcal clearance but leads to higher risk of development of IRIS. It may be prudent to delay initiation of ART until induction (the first 2 weeks) or till completion of the total induction/consolidation phase (i.e. 10 weeks).

All patients initiated with ART should be carefully followed up for development of IRIS. Paradoxical HIV associated CM-IRIS occurs in 6%–45% of patients, who received ART. Clinically it is difficult to differentiate relapse vs paradoxical CM-IRIS and there is no laboratory test available for diagnosis of paradoxical CM-IRIS. Risk factors for paradoxical CM-IRIS are a high organism/antigen load at baseline, acellular CSF, and early initiation of ART with rapid immune restoration. CSF examination showing evidence of inflammations with raised white cells, proteins and opening pressure with reduced glucose and sterile CSF supports the diagnosis of paradoxical IRIS while positive CSF cryptococcal culture, virologic failure, and lower CSF inflammatory profile supports the diagnosis of cryptococcal meningitis relapse. India ink and a CrAg test in the CSF have limited diagnostic utility for distinguishing IRIS from relapse. CrAg titers generally remain positive and slowly decline over months to years at variable rates after successful CM treatment. A four-fold rise in CSF CrAg titer can be early indication of relapse.

Treatment of paradoxical CM-IRIS

CM-IRIS is a life-threatening condition. Management of raised ICP with lumbar tap and a short course of steroid i.e prednisolone 0.5–1.0 mg/kg/day slowly tapering over 2–6 weeks is recommended by IDSA guideline for CM-IRIS. For steroid refractory and/or dependent cases can be treated by TNF-alpha inhibitors like thalidomide and adalimumab in both HIV and transplant patients.

Conclusions

CM is a life threatening fungal infection; predominantly involving immunocompromised patients with T cell dysfunction. Combination antifungal treatment is recommended for the treatment of CM. Management of raised ICP is critical in improving outcome.

References

1. Park BJ, Wannemuehler KA, Marston BJ, Govender N, Pappas PG, Chiller TM. Estimation of the current global burden of cryptococcal meningitis among persons living with HIV/AIDS. *Aids* 2009;23:525–30.
2. Bicanic T, Muzoora C, Brouwer AE, Meintjes G, Longley N, Taseera K, et al. Independent association between rate of clearance of infection and clinical outcome of HIV-associated cryptococcal meningitis: Analysis of a combined cohort of 262 patients. *Clin Infect Dis*. 2009; 49:702–9
3. Day JN, Chau TT, Wolbers M, et al. Combination antifungal therapy for cryptococcal meningitis. *N Engl J Med* 2013;368:1291–302.
4. Molloy SF, Kanyama C, Heyderman RS, et al; ACTA Trial Study Team. Antifungal Combinations for Treatment of Cryptococcal Meningitis in Africa. *N Engl J Med*. 2018 Mar 15;378(11):1004–1017.
5. Jarvis JN, Leeme TB, Molefi M, et al. Short-course High-dose Liposomal Amphotericin B for Human Immunodeficiency Virus-associated Cryptococcal Meningitis: A Phase 2 Randomized Controlled Trial. *Clin Infect Dis*. 2019 Jan 18;68(3):393–401.
6. Rolfes MA, Hulsiek KH, Rhein J, et al. The effect of therapeutic lumbar punctures on acute mortality from cryptococcal meningitis. *Clin Infect Dis*. 2014 Dec 1;59(11):1607–14.
7. Boulware DR, Meya DB, Muzoora C, et al; COAT Trial Team. Timing of antiretroviral therapy after diagnosis of cryptococcal meningitis. *N Engl J Med*. 2014 Jun 26;370(26):2487–98.

8. Bisson GP, Molefi M, Bellamy S, et al. Early versus delayed antiretroviral therapy and cerebrospinal fluid fungal clearance in adults with HIV and cryptococcal meningitis. *Clinical infectious diseases : an official publication of the Infectious Diseases Society of America* 2013;56:1165-73
9. Haddow LJ, Colebunders R, Meintjes G, et al; International Network for the Study of HIV-associated IRIS (INSHI). Cryptococcal immune reconstitution inflammatory syndrome in HIV-1-infected individuals: proposed clinical case definitions. *Lancet Infect Dis.* 2010 Nov;10(11):791-802.
10. Beardsley J, Wolbers M, Kibengo FM, Ggayi AB, Kamali A, Cuc NT, Binh TQ, Chau NV, Farrar J, Merson L, Phuon L, Thwaites G, Van Kinh N, Thuy PT, Chierakul W, Siriboon S, Thiansukhon E, Onsanit S, Supphamongkholchaikul W, Chan AK, Heyderman R, Mwinjiwa E, van Oosterhout JJ, Imran D, Basri H, Mayxay M, Dance D, Phimmason P, Rattanavong S, Lalloo DG, Day JN; CryptoDex Investigators. Adjunctive Dexamethasone in HIV-Associated Cryptococcal Meningitis. *N Engl J Med.* 2016 Feb 11;374(6):542-54.

THE STORY OF THE RED FUNGUS

**Sampada Patwardhan¹, Bharat Purandare²,
Atul Mulay³, M. R. Shivaprakash⁴**

¹Consultant, Microbiology, Deenanath Mangeshkar Hospital, Pune.

²Consultant, Infectious Diseases, Deenanath Mangeshkar Hospital, Pune.

³Consultant, Nephrology, Deenanath Mangeshkar Hospital, Pune.

⁴ Professor, Department of Medical Microbiology, PGIMER, Chandigarh.

Case Details

SP, 55 yrs old gentleman, resident of a small town in south Maharashtra presented to our hospital emergency in July 2017 with complaints of severe pain in lower abdomen and left flank, dysuria and mild fever for 4-5 days. Apart from hypertension for 2 years the patient gave no history of any other chronic comorbidities. He gave history of recurrent renal stones since 3 yrs for which he underwent procedures like PCNL & bilateral DJ stent placement and removal in 2015. Fifteen days prior to this admission he had undergone left DJ stenting in a private hospital outside for left midureteric 19 mm calculus with left hydronephrosis.

The patient was clinically stable on presentation. Significant laboratory findings were, raised serum creatinine (6.87 mg%) and serum urea (180 mg%), eosinophilia (absolute count 1370/mm³). Urine routine examination showed plenty pus cells/HPF with hematuria. X ray KUB revealed the DJ stent displaced, present in bladder (Fig.1) CT KUB showed enlarged left kidney with moderate hydronephrosis and proximal hydroureter and DJ stent displaced in the urinary bladder. With a diagnosis of acute on chronic kidney disease with UTI the patient was admitted and posted for cystoscopy, left ureteroscopy, ureteric catheterization and DJ stent removal.

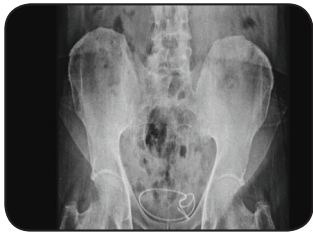


Fig 1 : X-ray KUB showing coiled stent in the bladder.

Preoperative urine culture yielded fungal growth with velvety white colonies on blood agar with no concomitant bacterial growth. KOH examination of the centrifuged whole urine sample showed hyaline, narrow, septate, acutely branching fungal hyphae. Fungal culture was repeated pre-operative on 2 more consecutive urine samples both showing presence of fungus on KOH examination and culture on Sabouraud's Dextrose Agar (SDA). Intraoperatively the urologist noted "furlike" growth on the coiled dislocated DJ stent in the urinary bladder. No calculus, SOL or fungal ball was noted inside the ureter or bladder. Stent with bladder urine were sent for fungal culture. In the lab the stent was scraped and subjected to KOH microscopy and culture on SDA. Whole sample of the bladder urine was centrifuged, and the deposit was processed for KOH microscopy and culture on SDA. Each of these on KOH examination showed similar hyaline, narrow, septate acutely branching fungal hyphae.

Fungal cultures of all specimens i.e. 3 pre-op urine samples, stent and bladder urine collected intra operatively was done on SDA with chloramphenicol, incubated at 37°C in BOD incubator and at room temperature. In the first week of incubation velvety white colonies with pale yellow reverse were observed in

all cultures. Identification of the fungus could not be done in this early phase of growth due to lack of sporulation. In the late second week of incubation the colonies were glabrous with greyish tinge and produced profuse rose red pigment that was rapidly diffusing and could be observed on the reverse too. Droplets of the red pigment were seen to be condensed on the petriplate lid (fig2).

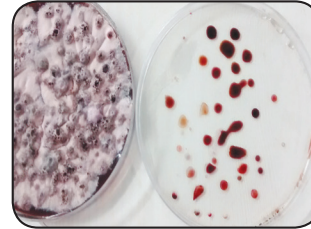


Fig 2: Fungal growth on SDA with red pigment.




Fig 3: LPCB mount showing the characteristic sporulation of Penicillium.

Micromorphology of all isolates on LPCB scotch tape examination showed slender, septate conidiophores, metulae with flask shaped phialides bearing conidia in chains forming brush like clusters, characteristic of *Penicillium* species (Fig.3).

With a presumptive identification of *Talaromyces marneffeii* (owing to the red pigment) the isolate was sent to the Reference Mycology Laboratory, PGIMER, Chandigarh for identification by DNA sequencing & antifungal DST. The fungus was identified as *Eupenicillium meridianum*. MIC of 0.03 µg/ml was reported for Amphotericin B, Voriconazole, Posaconazole, Caspofungin, Anidulafungin, Micafungin each.

The patient was discharged 4th day post op on Tab voriconazole 200 mg twice daily for 10 days. The patient was doing well on follow up visit 15 days later and is asymptomatic till date.

Discussion

Eupenicillium meridianum is the teleomorph synonym of *Penicillium rubidurum* (anamorph). Global Catalogue of Micro organisms describes *Eupenicillium meridianum* as having 14 strains commonly found in soil or drying wood. There has been only one publication on this fungus till date about the genomics of the organism. A pubmed search revealed no human infection reported till date.

Though we initially presumed the fungus to be *T. marneffeii*, the clinical setting and the growth characteristics of the fungus did not favor this. *T. marneffeii* is endemic in South East Asia especially Mainland China and causes opportunistic systemic mycoses in immunocompromised hosts especially in patients with AIDS. Disseminated infection involving lung, liver, spleen, bone marrow, skin is commonly found. It exhibits thermal dimorphism and exists in the yeast form in tissues and on culture incubation at 37°C. Our patient was HIV seronegative and immunocompetent, had never visited SE Asia and his disease was localized to the urinary tract.

The fungus showed hyphal forms in KOH mounts and grew as a red mould both at 37°C and room temperature. Apart from *T. marneffeii* variety of other *Talaromyces* and *Penicillium* species can produce pigments with red hues e.g. *T. purpurogenus*, *P. rubidurum*, *P. herquei*, *P. parvum*, *P. vinaceum*, *P. guttulosum*, *T. verruculosus*, *T. atroroseus*, *T. minioluteus*. These pigments occur as secondary metabolites produced by the fungi and are used as sources of ecofriendly dyes in textile, food and cosmetic industries.

Infections in humans caused by *Penicillium* spp other than *T. marneffeii* are rare. Trauma, surgery, prosthetic material, are commonly found as predisposing factors. Though commonly seen in immunocompromised patients, there have been a few reports of infections in immunocompetent patients. Lyratzopoulos G. et al reported three such cases of invasive disease; pulmonary infection in a patient with chronic granulomatous disease, cerebral disease due to *P. chrysogenum*, paravertebral infection due to *P. decumbens*. The authors also did a literature search on infections due to *Penicillium* spp other than *T. marneffeii* and from 1951 to 2000, found 31 such reported cases. *Penicillium piceum* infection presenting as pulmonary nodule and rib osteomyelitis in a patient with chronic granulomatous disease was reported by Santos P.E et al.

Pulmonary infection caused by *Talaromyces purpurogenus* was reported in a patient with multiple myeloma was reported in 2016.

Fungal infections of the urinary tract may follow instrumentation or catheterization. Most of the cases are a result of candida infection. Other rare reported cause includes *Aspergillus* spp. Ureteric stenting is a commonly performed endo urologic procedure. As with all prosthetic medical devices, ureteric stents can undergo colonization and biofilm formation by microorganisms. Infected stents can cause urinary tract infections, obstructive uropathy and can be a source of disseminated infection.

Our patient may probably have acquired the fungus from the contaminated stent or inadequately disinfected cystoscope or ureteroscope. It is recommended that prior to use the scopes should be thoroughly cleaned using enzymatic cleaners and should undergo high level disinfection with glutaraldehyde or H2O2 plasma sterilization. These standard practices are often sub optimally followed in small hospitals or nursing homes possibly due to lack of awareness or resources.

Though our patient was treated with oral voriconazole, given the fact that voriconazole does not achieve good concentration in the urinary tract, source control achieved by removing the stent must have resulted in clinical cure.

To our knowledge, this is the first reported case of infection due to *Eupenicillium meridianum*. The case highlights that on laboratory isolation of *Penicillium* species producing red pigment from clinical specimens, the possibility of non *marneffei* species should be considered especially in a clinical setting that is atypical for *T. marneffei*. It also emphasizes the need for optimal infection control practices especially when using endoscopic equipment.

References

1. http://www.mycobank.org/Biolomics.aspx?Table=Mycobank&MycoBankNr_330736
2. http://gcm.wfcc.info/strains.jsp?strain_number=&strain_name=Eupenicillium%20meridianum&marklog=strainnamelist
3. Gunasekaran S, Poorniammal R. Optimization of fermentation conditions for red pigment production from *Penicillium* sp. under submerged cultivation. *American Journal of Biotechnology*. 2008; volume 7 (12): 1894-1898.
4. Lyratzopoulos G, Ellis M, Nerringer R, Denning DW. Invasive infections due to *Penicillium* species other than *P. marneffei*. *J Infect*. 2002; 45(3): 184-195.
5. Santos PE, Piontelli E, Shea YR, Galluzzo ML, Holland SM et al. *Penicillium* infection: diagnosis and successful treatment in chronic granulomatous disease. *Med Mycol*. 2006; 44(8): 749-753.
6. Atalay A, Koc AN, Akyol G, Cakir N et al. Pulmonary infection caused by *Talaromyces purpurogenus* in a patient with multiple myeloma. *Le infezioni in Medicina*. 2016; 24(2):153 - 157.
7. Rao P. *Aspergillus* infection in urinary tract post-ureteric stenting. *Indian J Med Microbiol* 2015; 33:316-8.

TREATMENT FOR INVASIVE PULMONARY ASPERGILLOSIS IN RESISTANT HIV: A FLIGHT THROUGH DENSE FOG.

Sujata Rege, Tushar Patil, Rajeev Soman
Jupiter Hospital, Pune

IPA is not a very common OI in HIV patients. However when it does occur, it poses many difficulties due to drug interactions.

UM, 40/F, was HIV infected & on antiretroviral therapy (ART) since 2005. She failed NNRTI based ART & was changed to ATV/r (atazanavir/ ritonavir) TDF (tenofovir) 3TC (lamivudine) in 2017. She was diagnosed with Right eye Squamous cell Carcinoma, underwent orbital exenteration and received radiation and chemotherapy.

The current ART had also failed with CD4 <200 & VL 14000, hence it was changed to full dose Darunavir/Ritonavir (DRV/r 1200/200), Dolutegravir (DTG) and Lamivudine (3TC).

A few weeks later she presented with fever and cough and a thin walled cavity in Left Upper lobe was found (Fig. 1). Sputum culture grew *Aspergillus fumigatus*. Workup for TB, common & unusual bacterial causes of pneumonia was negative. Since the host factor (HIV with CD4 <200), radiological (cavitary lesion), mycological (Sputum culture growth of *A. fumigatus*) criteria were present, this was considered a case of Probable Invasive Pulmonary Aspergillosis (IPA).

She merited Voriconazole for IPA as it is superior to AmB (amphotericin B). However she was on DRV/r, which has considerable interactions with Voriconazole. Ritonavir inhibits CYP3A4, but induces CYP2C19 which metabolizes voriconazole, thereby decreasing voriconazole AUC by 39-82% and Cmax by 24%. The dose of Voriconazole is required to be doubled to 400mg twice daily when administered with low dose ritonavir (100 mg/day). However with a Ritonavir dose of 200 mg/day, attaining therapeutic levels of voriconazole would not be possible.

Since Voriconazole was to be used, DRV/r was temporarily stopped and only DTG + 3TC were continued. Extrapolating from the results of DAWNING, DOLUMONO and DOMONO trials, ART with only 2 drugs (DTG + 3TC) would be expected to work although only temporarily. The duration of treatment for IPA is based on clinical and radiological resolution and may range from 3-50 weeks. In this case there was resolution of cough & fever, improvement in CD4 count to 158, VL to 303 copies/ml on this two drug ART. Voriconazole trough level was found to be 3.7 microgram/ml. X-ray showed resolution of the cavitary lesion at 8 weeks (Fig. 2). Voriconazole was stopped & DRV/r was reinstated a few days later as part of ART along with DTG & 3TC. The patient is doing well on follow up.

In conclusion, careful consideration of drug interactions, extrapolation from various trial results, clinical judgement, TDM for voriconazole & close follow-up is helpful in managing such cases.

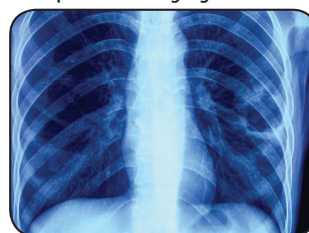


Figure 1 : Before Therapy

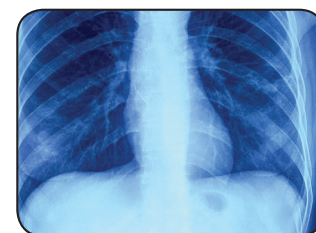


Figure 2 : After 8 weeks of Voriconazole

References

1. De Pauw B, Walsh TJ, Donnelly JP, et al. Revised definitions of invasive fungal disease from the European Organization for Research and Treatment of Cancer/Invasive Fungal Infections Cooperative Group and the National Institute of Allergy and Infectious Diseases Mycoses Study Group (EORTC/MSG) Consensus Group. *Clin Infect Dis*. 2008; 46:1813-21.
2. Aboud M, Kaplan M, Lombaard J et al. Superior efficacy of dolutegravir (DTG) plus 2 nucleoside reverse transcriptase inhibitors (NRTIs) compared with lopinavir/ritonavir (LPV/RTV) plus 2 NRTIs in second-line treatment: interim data from the DAWNING study. (Paris, France; July 23–26): 8
3. Oldenbuechtel C, Wolf E, Ritter A, et al. Dolutegravir monotherapy as treatment de-escalation in HIV-infected adults with virological control: DoluMono cohort results. *Antivir Ther*. 2017; 22 (2):169–72.
4. Wijting I, Rokx C, Boucher C, et al. Dolutegravir as maintenance monotherapy for HIV (DOMONO): a phase 2, randomised non-inferiority trial. *Lancet HIV*. 2017; 4(12):e547–e554. 10.1016/S2352-3018(17)30152-2.
5. Ullmann AJ, Aguado JM, Arikan-Akdagli S, et al. Diagnosis and management of *Aspergillus* diseases: executive summary of the 2017 ESCMID-ECMM-ERS guideline. *Clin Microbiol Infect*. 2018; 24(suppl 1):e1–e38.

About FISF

The purpose of the Fungal Infections Study Forum is to conduct educational activities, undertake epidemiological and clinical studies and to promote research activities on invasive fungal infections. The results of such research would benefit the clinicians, mycologists and the general public. The trust was formed in view of emergence of Invasive fungal infections (IFIs) in India which is posing a serious challenge to the haematologists, critical care providers, ID specialists, pulmonologists, neurologists, medical mycologists and many other clinicians handling serious and immunocompromised patients. The trust is the independent working consisting of clinicians and mycologists and instituted on 3rd March 2012 at Mumbai, India. To know more about us visit www.fisftrust.org.